

# Patellofemoral Kinematics During Weight-Bearing and Non-Weight-Bearing Knee Extension in Persons With Lateral Subluxation of the Patella: A Preliminary Study

Christopher M. Powers, PT, PhD<sup>1</sup>

Samuel R. Ward, PT<sup>2</sup>

Michael Fredericson, MD<sup>3</sup>

Marc Guillet, PT, MS<sup>4</sup>

Frank G. Shellock, PhD<sup>5</sup>

**Study Design:** Single-group, repeated-measures design.

**Objective:** To compare patellofemoral joint kinematics during weight-bearing and non-weight-bearing knee extension in persons with lateral subluxation of the patella.

**Background:** The only previous study to quantify differences in patellofemoral joint kinematics during weight-bearing and non-weight-bearing tasks was limited in that static loading conditions were utilized. Differences in patellofemoral joint kinematics between weight-bearing and non-weight-bearing conditions have not been quantified during dynamic movement.

**Methods and Measures:** Six females with a diagnosis of patellofemoral pain and lateral subluxation of the patella participated. Using kinematic magnetic resonance imaging, axial images of the patellofemoral joint were obtained as subjects extended their knees from 45° to 0° during non-weight-bearing (5% body weight resistance) and weight-bearing (unilateral squat) conditions. Measurements of patellofemoral joint relationships (medial/lateral patellar displacement and patellar tilt), as well as femur and patella rotations relative to an external reference system (ie, the image field of view), were obtained at 3° increments during knee extension.

**Results:** During non-weight-bearing knee extension, lateral patellar displacement was more pronounced than during the weight-bearing condition between 30° and 12° of knee extension, with statistical significance being reached at 27°, 24°, and 21°. No differences in lateral patellar tilt were observed between conditions ( $P = .065$ ). During the weight-bearing condition, internal femoral rotation was significantly greater than during the non-weight-bearing condition as the knee extended from 18° to 0°. During the non-weight-bearing condition, the amount of lateral

patellar rotation was significantly greater than during the weight-bearing condition throughout the range of motion tested.

**Conclusions:** The results of this study demonstrated that lateral patellar displacement was more pronounced during non-weight-bearing knee extension compared to weight-bearing knee extension in persons with lateral patellar subluxation. In addition, the results of this investigation suggest that the patellofemoral joint kinematics during non-weight-bearing could be characterized as the patella rotating on the femur, while the patellofemoral joint kinematics during the weight-bearing condition could be characterized as the femur rotating underneath the patella. *J Orthop Sports Phys Ther* 2003;33:677-685.

**Key Words:** magnetic resonance imaging, patellar tracking, patellofemoral joint

<sup>1</sup> Associate Professor, Director, Musculoskeletal Biomechanics Research Laboratory, Department of Biokinesiology and Physical Therapy, University of Southern California, Los Angeles, CA.

<sup>2</sup> PhD candidate, Department of Biokinesiology and Physical Therapy, University of Southern California, Los Angeles, CA.

<sup>3</sup> Associate Professor, Division of Physical Medicine and Rehabilitation, Department of Orthopaedic Surgery, Stanford University School of Medicine, Stanford, CA.

<sup>4</sup> Owner, Apex Physical Therapy, Palo Alto, CA.

<sup>5</sup> Adjunct Clinical Professor of Radiology, Keck School of Medicine, University of Southern California and Institute for Magnetic Resonance Safety, Education, and Research, Los Angeles, CA.

This study's protocol was approved by the Stanford University Institutional Review Board.

Address all correspondence to Dr. Powers, 1540 E. Alcazar St. CHP-155, Los Angeles, CA 90089-9006. E-mail: powers@usc.edu.

**E**xcessive lateral tracking of the patella has been hypothesized to be contributory to the development of patellofemoral pain (PFP).<sup>3-5,8,9</sup> Clinical assessment of lateral patellar tracking, however, is a difficult and imprecise task, owing to the inability to directly visualize the relation-

ship between the patella and the trochlear groove. In lieu of this limitation, various forms of imaging (ie, radiographs, computerized tomography, magnetic resonance imaging [MRI], and video fluoroscopy) have been employed to make the diagnosis of patellar malalignment or lateral patellar subluxation.<sup>1,7,15,16</sup>

Kinematic magnetic resonance imaging (KMRI) is an imaging method that has been reported to give important diagnostic information concerning the patellofemoral joint.<sup>13,15-17</sup> This technique utilizes a fast spoiled gradient-recalled acquisition in the steady state (spoiled GRASS) pulse sequence that allows rapid imaging during active movement.<sup>13</sup> The advantage of KMRI over traditional imaging approaches is that the joint can be imaged dynamically (as opposed to incremental passive positioning). Therefore, the contribution of quadriceps contraction with respect to patellofemoral kinematics can be assessed.<sup>13,18</sup>

Several authors have described patellofemoral kinematics in persons with PFP.<sup>10,12,18,19,23</sup> While these studies have varied with respect to how patellar subluxation is determined (ie, quantitative measurements vs qualitative criterion), it is well accepted that lateral subluxation occurs during the last 20° of knee extension.<sup>2,10</sup> However, a limitation of most studies that have used KMRI was the fact that patellofemoral kinematics were assessed under non-weight-bearing conditions.

Using computerized tomography (CT), differences in patellar position between weight-bearing and non-weight-bearing conditions was quantified by Doucette and Child.<sup>2</sup> Although these authors reported improved patellofemoral joint congruence in persons with PFP during the weight-bearing condition, it should be noted that scans were obtained statically and that the weight-bearing task was performed in a nonfunctional supine position. Only 1 investigation has quantified patellar motion using KMRI under upright, weight-bearing conditions.<sup>20</sup> This study, however, studied asymptomatic individuals and no comparisons were made to non-weight-bearing movements. An interesting observation of this study was that lateral patellar tilt appeared to be the result of femoral internal rotation (femur rotating underneath the patella) in 47% of all cases evaluated (19 out of 40). Although this phenomenon was not quantified, such an observation suggests that femoral internal rotation may play a role in abnormal patellofemoral kinematics during weight-bearing activities.

Using KMRI techniques, the purpose of this study was to compare patellofemoral kinematics during weight-bearing and non-weight-bearing conditions in persons with lateral subluxation of the patella. A secondary purpose of this study was to quantify the role of patellar and femoral rotation in contributing to patellofemoral kinematics in this population. We hypothesized that lateral patellar displacement and lateral patellar tilt would be more pronounced in the

non-weight-bearing condition as compared to the weight-bearing condition, and that femoral rotation (as opposed to patellar rotation) would contribute to lateral patellar displacement and lateral patellar tilt in the weight-bearing condition.

## METHODS

### Subjects

Six female subjects with a diagnosis of PFP (mean age, 32 years; age range, 15-39 years) participated in this study. Subjects were recruited from sports medicine clinics at Stanford University and were screened through a physical examination to rule out ligamentous instability, meniscal injury, and patellar tendonitis. To ensure consistency with subject screening, all subjects were evaluated by the same physician.

Only individuals with histories relating to overuse or insidious onset were accepted for participation in this investigation. Each subject's pain was readily reproducible with at least 2 of the following activities commonly associated with PFP: stair ascent or descent, squatting, kneeling, prolonged sitting, or isometric quadriceps contraction.<sup>6,11</sup> Only subjects with documented lateral patellar subluxation (as determined through the KMRI procedure described below) were included. Subjects were excluded from the study if they reported previous knee surgery or acute traumatic patellar dislocation. Prior to participation, all procedures were explained and each subject provided written informed consent to the MRI study. This study protocol was approved by the Stanford University Institutional Review Board.

### Instrumentation

Dynamic imaging of the patellofemoral joint was performed using a vertically open (56-cm opening) MR system (0.5 T, Signa SP; General Electric Medical Systems, Milwaukee, WI) developed for interventional MR procedures. This system was equipped with pulse sequence programming and real-time interactive MR imaging capabilities. The vertically opened design of this MR system permitted subjects to be imaged during both weight-bearing (standing) and non-weight-bearing (seated) conditions.

Axial images of the patellofemoral joint were obtained using a flexible transmit-receive surface coil and a fast spoiled gradient-recalled acquisition in the steady state (spoiled GRASS) pulse sequence. MR images were obtained at a rate of 1 image per 0.75 seconds, using the following parameters: repetition time (TR), 10.3 milliseconds; echo time (TE), 2.7 milliseconds; flip angle, 40°; field of view, 35 cm × 18 cm; matrix size, 256 × 128; number of excitations, 2.

## Procedures

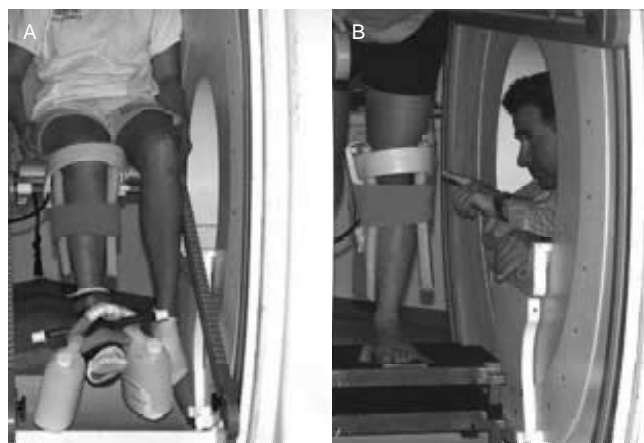
Prior to imaging, subjects were screened for the MRI environment using a questionnaire, and were asked to remove all metallic objects. Imaging during the non-weight-bearing condition was performed in the seated position with the hips flexed to 90°. In order to match the quadriceps demand during the weight-bearing task, knee extension was performed from 45° of flexion to full knee extension against a resistance of 5% body weight. This weight was chosen as a preliminary study demonstrated that this resistance resulted in electromyographic activity of the quadriceps that was comparable to the weight-bearing condition at 30° of knee flexion. As metallic objects are not permitted within the magnetic field, the weight consisted of a plastic jug filled with water that was strapped to a custom-made boot fixed to the distal tibia (Figure 1A).

Imaging during the weight-bearing condition was performed barefoot in a single-limb stance position (Figure 1B). During this task, subjects assumed a natural standing posture with the foot in a normal amount of toe-out (3°-5°). Subjects were instructed to squat from a fully extended position to 45° of flexion and then return to the extended position. No attempt was made to control the frontal- and transverse-plane motions of the lower extremity during this procedure. To maintain balance during the single-limb squat, subjects were permitted to apply light finger pressure to the railing within the MRI system opening.

During the weight-bearing and non-weight-bearing conditions, the imaging plane was held constant while the subject extended the knee. In all cases, the image plane was perpendicular to the patella when the knee was extended. This meant that the image plane was rotated 90° when the subjects went from the seated to standing conditions. Thus, an axial view of the patellofemoral joint always was obtained.

For both conditions, subjects were instructed to extend the knee slowly in a consistent manner, moving through the 45° arc of motion over the course of 11 seconds (approximately 4° per second). A plastic goniometer placed on the lateral aspect of the knee allowed one of the investigators to monitor the range of motion and rate of movement during the training and data collection sessions (Figure 1B). Given the rate of 1 image per 0.75 seconds, this speed of movement permitted 15 images to be obtained at approximate 3° increments over the entire range of motion.

As the patella moves superiorly within the trochlear groove when the knee extends, use of a single imaging plane would not be sufficient to capture the midsection of the patella. To overcome this problem, subjects were required to repeat the weight-bearing and non-weight-bearing procedures 3 times, with the section location (ie, image plane) being moved proxi-



**FIGURE 1.** Weight-bearing and non-weight-bearing movements inside the vertically open, magnetic resonance imaging system. (A) Non-weight-bearing knee extension against 5% of body weight. (B) Weight-bearing single-limb squat. The flexible surface coil surrounding the knee did not restrict or influence knee motion.

mally for each trial. This resulted in 3 images being obtained at each knee flexion angle. In all cases, KMRI assessment was repeated if the rate of knee extension was too fast, too slow, or not performed in a smooth manner. In addition, imaging was repeated if 15 adequate images were not obtained. An adequate image was one in which the medial and lateral borders of the midsection of the patella, the trochlear groove, and the posterior femoral condyles were well defined.<sup>13</sup>

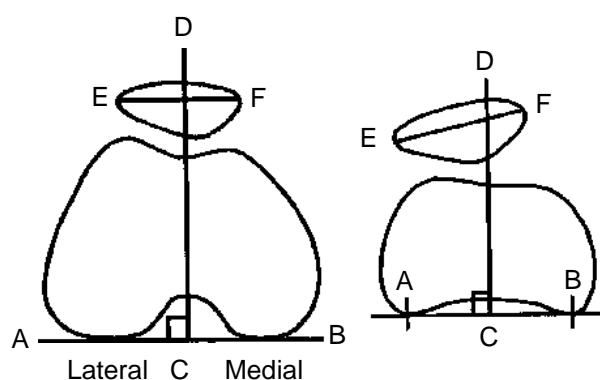
All subjects performed the non-weight-bearing task first, followed by the weight-bearing condition. Once the non-weight-bearing trials were completed, the images were screened by an experienced radiologist to determine whether subjects had lateral subluxation. This was done qualitatively using the criteria established by Shellock et al.<sup>17</sup> Briefly, lateral subluxation was defined as the median ridge of the patella being lateral relative to the centermost part of the femoral trochlear groove at full knee extension. If a subject demonstrated lateral patellar subluxation, imaging in the weight-bearing condition was performed. If a subject did not have evidence of lateral patellar subluxation, the subject's participation in the study was terminated.

## Data Analysis

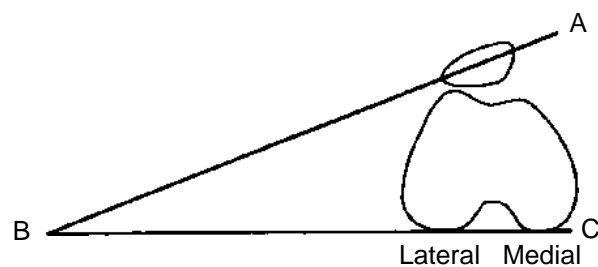
For purposes of this investigation, only data from 30° to 0° of knee extension were analyzed. This decision was based on previous work, which demonstrated that patellar subluxation occurs during the last 20° of knee extension.<sup>10</sup> In addition, only the kinematic data that corresponded to the concentric phase of the single-limb squat maneuver (extending from 30° of flexion to full extension) were considered. This was done to match the non-weight-bearing condition, thereby controlling for the possible confounding effect of muscle contraction type (ie, concentric vs eccentric).

Prior to analysis, all images were screened to ascertain which of them best visualized the midsection of the patella (maximum patellar width) at each angle of knee flexion. Once this was determined, measurements for these images were obtained. Only images containing a midpatella slice were analyzed.

Medial/lateral patellar displacement was assessed using the bisect offset index as described by Powers et al.<sup>13</sup> The bisect offset was measured by drawing a line connecting the posterior femoral condyles and then projecting a perpendicular line anteriorly through the deepest point (apex) of the trochlear groove. This line intersected the patellar width line, which connected the 2 widest points of the patella (Figure 2). To obtain data when the trochlear groove was flattened, the perpendicular line was projected anteriorly from the bisection of the posterior



**FIGURE 2.** Methods used to measure lateral patellar displacement (bisect offset index). Line AB connected the posterior femoral condyles, then a perpendicular line was projected anteriorly through the deepest portion of the trochlear groove (line CD) to a point where it bisected the patellar width line (line EF) (left). When the trochlear groove was not visible, the perpendicular line was projected anteriorly from the bisection of the posterior condylar line (right). This measurement was reported as the percentage of patellar width lateral to midline (line CD). Reprinted with permission from *Medicine and Science in Sports and Exercise* 1999;31:1716.



**FIGURE 3.** Method used to assess patellar tilt. This angle was defined as the angle formed by lines joining the maximum width of the patella (line AB) and the posterior femoral condyles (line BC). Reprinted with permission from *Medicine and Science in Sports and Exercise* 1999;31:1716.

condylar line (Figure 2).<sup>13</sup> The bisect offset was representative of the extent of the patella lateral or medial to the midline and was expressed as a percentage of the total patellar width.

Medial/lateral patellar tilt was measured as the angle formed by the line joining the maximum width of the patella and the line joining the posterior femoral condyles (Figure 3).<sup>13</sup> Tilt measurements were reported in degrees.

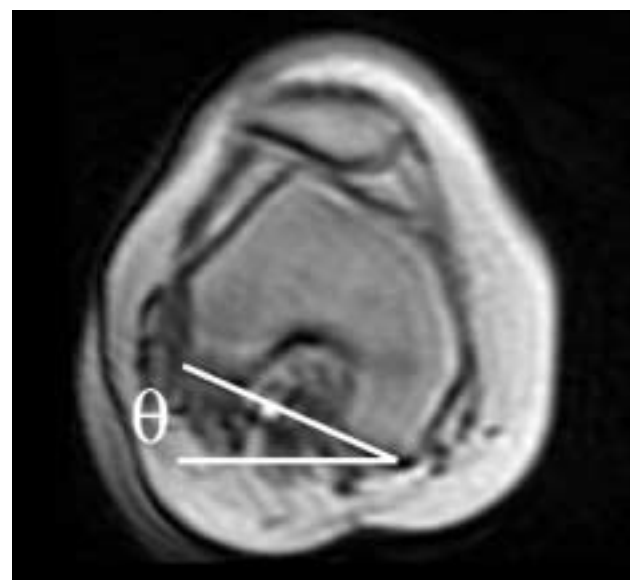
Medial/lateral femoral rotation (transverse plane) was quantified as the angle formed by the line joining the posterior femoral condyles and a line parallel to the horizontal orientation of the field of view (Figure 4). Because the *x* and *y* orientation of the field of view was held constant during imaging, this angle represented the amount of femoral rotation during a particular task in relation to an external frame of reference. Femoral rotation measurements were reported in degrees.

As with femoral rotation, patella rotation (transverse plane) was quantified as the angle formed by the line defining the maximum patella width and a line parallel to the horizontal orientation of the field of view (Figure 5). Patellar rotation measurements were reported in degrees.

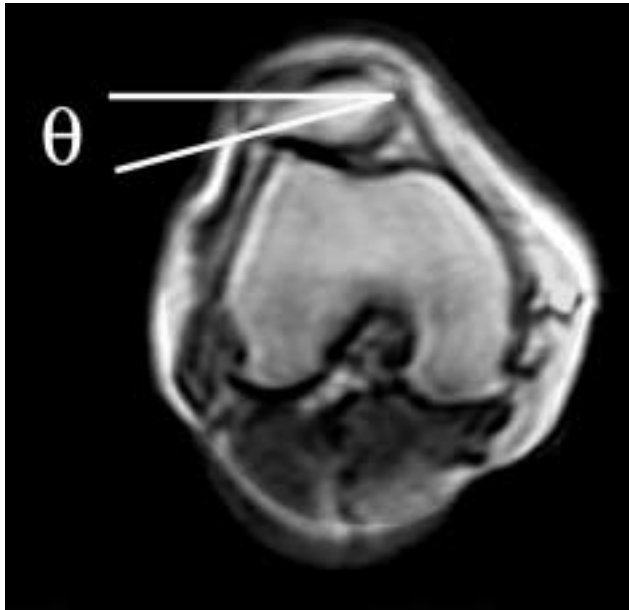All measurements were made using a custom-written macro for Scion image software (Scion Corp., Frederick, MD). Values for bisect offset, patellar tilt, femoral rotation, and patellar rotation represented the average of 2 measurements.

### Measurement Reliability and Error Analysis

All data were obtained by the same investigator and demonstrated excellent repeatability for the patellar



**FIGURE 4.** Method used to assess femoral rotation. This angle ( $\theta$ ) was defined by the intersection of a line connecting through the posterior femoral condyles and a line parallel to the horizontal axis of the field of view.



**FIGURE 5.** Method used to assess patellar rotation. This angle ( $\theta$ ) was defined by the intersection of a line passing through the maximum width of the patella and a line parallel to the horizontal axis of the field of view.

displacement and patellar tilt measurements in a previously published study.<sup>21</sup> This same investigator also demonstrated excellent repeatability for the femoral rotation and patellar rotation measurements, as determined in a preliminary analysis ( $ICC_{3,2} = 0.99$  and  $0.96$ , respectively).

As the image plane was held constant during each trial, movement of the femur in the sagittal, frontal, or transverse planes could have influenced the measurements obtained in this study. To address this issue, a separate error analysis was conducted.<sup>22</sup> A cadaveric patella was rigidly fixed to a femur and the whole femur was placed into a custom nonferromagnetic jig. This jig allowed the patellofemoral joint to be imaged using imaging parameters identical to those of the current study as the femur was moved through known degrees of sagittal plane ( $0^{\circ}$ - $30^{\circ}$  flexion), frontal plane ( $5^{\circ}$  abduction- $30^{\circ}$  adduction), and transverse plane ( $0^{\circ}$ - $30^{\circ}$  internal rotation) motions. Increasing motion in any single or combined plane did not produce systematic increases in measurement error.<sup>22</sup> Measurement error for the bisect offset index (2% of patellar width), patellar tilt angle ( $2^{\circ}$ ), femoral rotation ( $2^{\circ}$ ), and patellar rotation ( $2^{\circ}$ ) were similar to the measurement errors associated with repeated measurements of the same image.

### Statistical Analysis

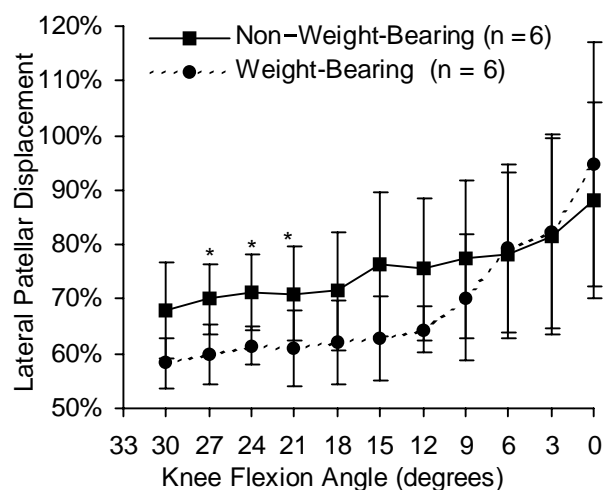
To determine whether patellar or femoral kinematics varied between weight-bearing and non-weight-bearing conditions, a  $2 \times 11$  (condition  $\times$  knee flexion angle) ANOVA with repeated measures was per-

formed. This analysis was conducted for each dependent variable (bisect offset index, patellar tilt angle, femoral rotation, and patellar rotation). Significant main effects were reported if there were no significant interactions. If a significant interaction was identified, individual effects were analyzed separately. SPSS statistical software (SPSS, Inc., Chicago, IL) was used for all analyses. Significance levels were set at  $P < .05$ .

### RESULTS

The ANOVA results for the bisect offset index did not show a significant condition effect; however, a significant condition  $\times$  knee flexion angle interaction was found ( $F_{1,10} = 2.13$ ,  $P = .039$ ). Post hoc analysis revealed significantly greater lateral displacement of the patella in the non-weight-bearing condition as compared to the weight-bearing condition, as the knee extended from  $27^{\circ}$  to  $21^{\circ}$  (Figure 6). No differences in bisect offset were observed at  $30^{\circ}$  or between  $18^{\circ}$  and  $0^{\circ}$ . The largest difference in bisect offset between the 2 conditions was 13% of patellar width (76% vs 63% of patellar width), which occurred at  $15^{\circ}$  of knee flexion (Figure 6).

With respect to patellar tilt, there was no significant condition effect ( $F_{1,10} = 5.54$ ,  $P = .065$ ) or condition  $\times$  knee flexion angle interaction. When averaged across all knee flexion angles, lateral patellar tilt in the non-weight-bearing condition was greater than the lateral patellar tilt in the weight-bearing condition ( $15^{\circ}$  vs  $10^{\circ}$  [Figure 7]); however, this difference was not statistically significant. The largest difference between weight-bearing and non-weight-bearing conditions was  $7^{\circ}$  ( $12^{\circ}$  vs  $5^{\circ}$ ) and occurred at  $24^{\circ}$  of knee flexion (Figure 7).



**FIGURE 6.** Comparison of lateral patellar displacement (percent of patellar width lateral to midline; bisect offset index) between non-weight-bearing and weight-bearing conditions. \*Significant differences ( $P < .05$ ). Error bars correspond to  $\pm 1$  SD.

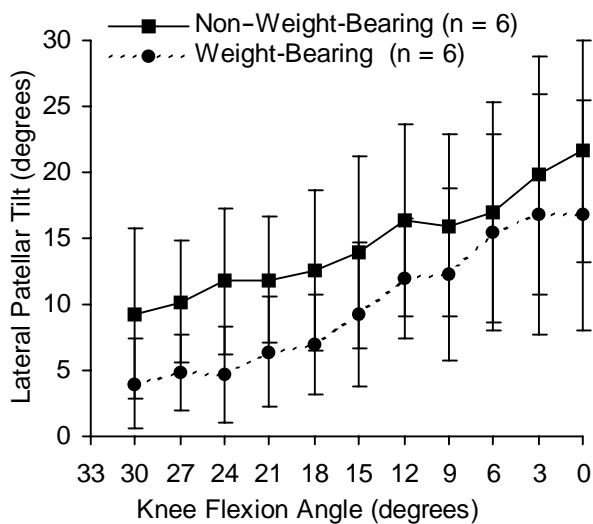


FIGURE 7. Comparison of patellar tilt between non-weight-bearing and weight-bearing conditions. No significant differences ( $P > .05$ ) were found between conditions. Error bars correspond to  $\pm 1$  SD.

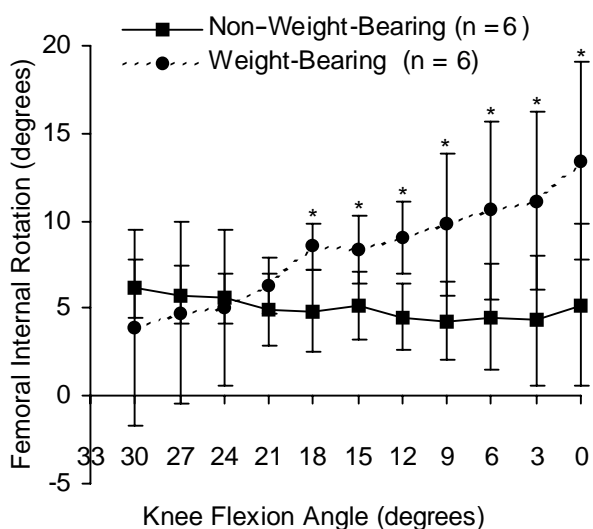


FIGURE 8. Comparison of femoral internal rotation between non-weight-bearing and weight-bearing conditions. \*Significant differences ( $P < .05$ ). Error bars correspond to  $\pm 1$  SD.

The ANOVA results for femoral rotation did not show a significant condition effect. However, a significant condition  $\times$  knee flexion angle interaction was found ( $F_{1,10} = 35.71$ ,  $P < .001$ ). Post hoc analysis revealed significantly greater femoral internal rotation in the weight-bearing condition as compared to the non-weight-bearing condition as the knee extended from 18° to 0° (Figure 8). The largest difference in femoral internal rotation between the 2 conditions was 8° (13° vs 5°) and occurred at 0° of knee flexion (Figure 8).

The ANOVA results for patellar rotation demonstrated a significant condition effect ( $F_{1,10} = 21.39$ ,  $P = .006$ ) and no condition  $\times$  knee flexion angle

interaction. When averaged across all knee flexion angles, there was significantly greater lateral patellar rotation in the non-weight-bearing condition as compared to the weight-bearing condition (9.5° vs 1.5° [Figure 9]). The largest difference in lateral patellar rotation between the 2 conditions was 13° (16° vs 3°) and occurred at 0° of knee flexion (Figure 9).

## DISCUSSION

The purpose of this preliminary study was to compare patellofemoral kinematics during weight-bearing and non-weight-bearing conditions in persons with lateral subluxation of the patella. As average values for bisect offset and lateral patellar tilt in pain-free individuals has been reported to be 54% of patellar width and 5.5°, respectively,<sup>13</sup> the individuals evaluated in the current study appeared to demonstrate abnormal patellofemoral kinematics during terminal knee extension (ie, 10°-0°), regardless of the task performed (Figures 6 and 7). Consistent with previous studies, patellar malalignment was most pronounced near full knee extension, indicating that this is the position of patellar instability.<sup>10</sup>

The results of this study provide partial support for our hypothesis that abnormal patellofemoral joint kinematics would be more pronounced in the non-weight-bearing condition as compared to the weight-bearing condition. With respect to lateral patellar displacement, a 15% greater bisect offset value was observed from 30° to 12° of knee extension, with statistical significance being reached at 27°, 24°, and 21° (Figure 6). On average, there was a 33% increase in lateral patellar tilt during the non-weight-bearing condition throughout the entire range of motion;

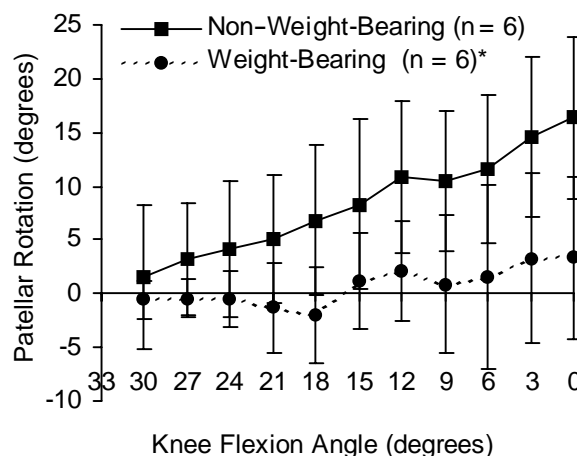


FIGURE 9. Comparison of patellar rotation between non-weight-bearing and weight-bearing conditions. \*The patellar rotation during non-weight-bearing was greater than during the weight-bearing condition when averaged across all knee flexion angles ( $P < .05$ ). Negative values indicate medial patellar rotation; positive values indicate lateral patellar rotation. Error bars correspond to  $\pm 1$  SD.

however, this observed difference was borderline with respect to statistical significance ( $P = .065$  [Figure 7]). The lack of significance for the patellar tilt variable can be explained by the small sample size that was utilized in this preliminary study. For example, a post hoc power/sample size calculation revealed that the power for this variable was only 0.40 and that 17 subjects would be needed to find statistical significance (assuming an  $\alpha$  of .05, 80% power, and a minimal clinically significant difference of  $5^\circ$ ). Despite the small sample size, the observed differences in lateral patellar displacement and lateral patellar tilt between the non-weight-bearing and weight-bearing conditions tend to support the static measurements obtained by Doucette and Child,<sup>2</sup> who found greater degrees of patellar malalignment under non-weight-bearing conditions.

The secondary purpose of this study was to quantify the role of patellar and femoral motions in contributing to patellofemoral joint kinematics. When evaluating the individual rotations of the patella and femur in the transverse plane, distinct patterns were observed between the weight-bearing and non-weight-bearing conditions. For example, increasing femoral internal rotation was observed as the knee extended during the weight-bearing condition, reaching a peak of  $13^\circ$  at full knee extension. Conversely, femoral internal rotation changed very little during the non-weight-bearing condition, averaging  $5.2^\circ$  over the entire range of knee extension (Figure 8). The lack of femoral rotation during non-weight-bearing is not surprising, given that the femur was relatively fixed in the seated position.

In contrast, the pattern of patellar rotation was opposite of that observed with the femur. During the non-weight-bearing condition, lateral patellar rotation progressively increased as the knee extended, reaching a maximum value of  $16^\circ$  at full knee extension. Conversely, patellar rotation changed very little during the weight-bearing condition (Figure 9).

The contribution of femoral and patellar rotations with respect to these subjects' patellofemoral kinematics can be visualized in Figures 10 and 11. In regard to patellar tilt, in the non-weight-bearing condition, lateral patellar tilt appears to be the result of the patella rotating laterally on a relatively horizontal femur (Figure 10A). In the weight-bearing condition, however, it is evident that the amount of lateral patellar tilt is due to femoral internal rotation, as the patella remains relatively horizontal (Figure 10B). A similar phenomenon can be seen with lateral patellar displacement. During the non-weight-bearing condition, lateral patellar displacement appears to be the result of the patella moving laterally on the fixed femur (Figure 11A). However, it is evident that femoral internal rotation influenced the degree of lateral patellar displacement during the weight-bearing condition (Figure 11B).

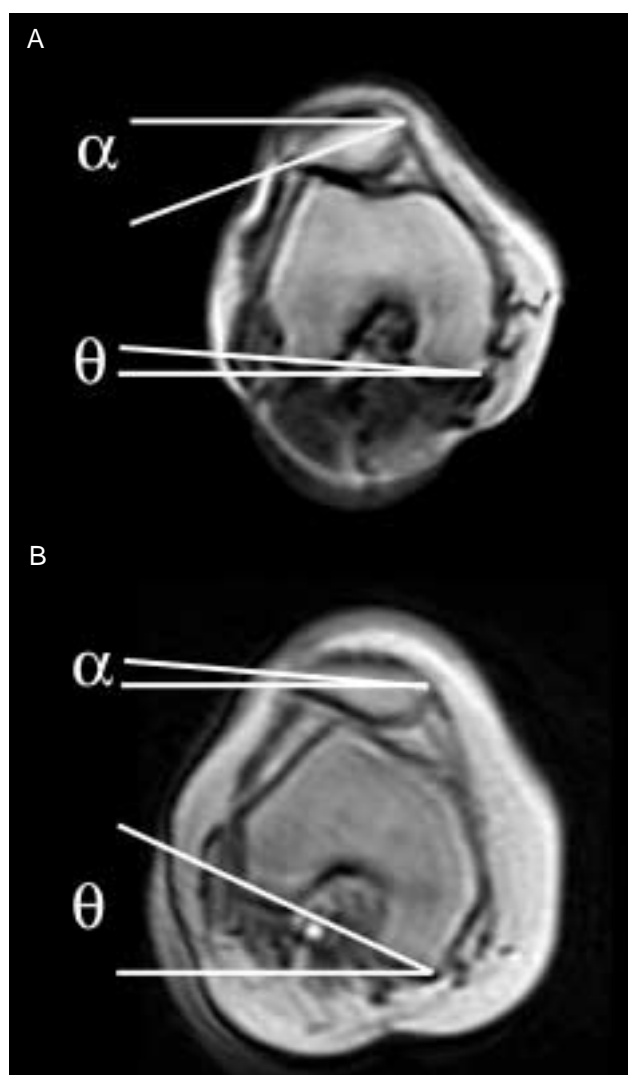
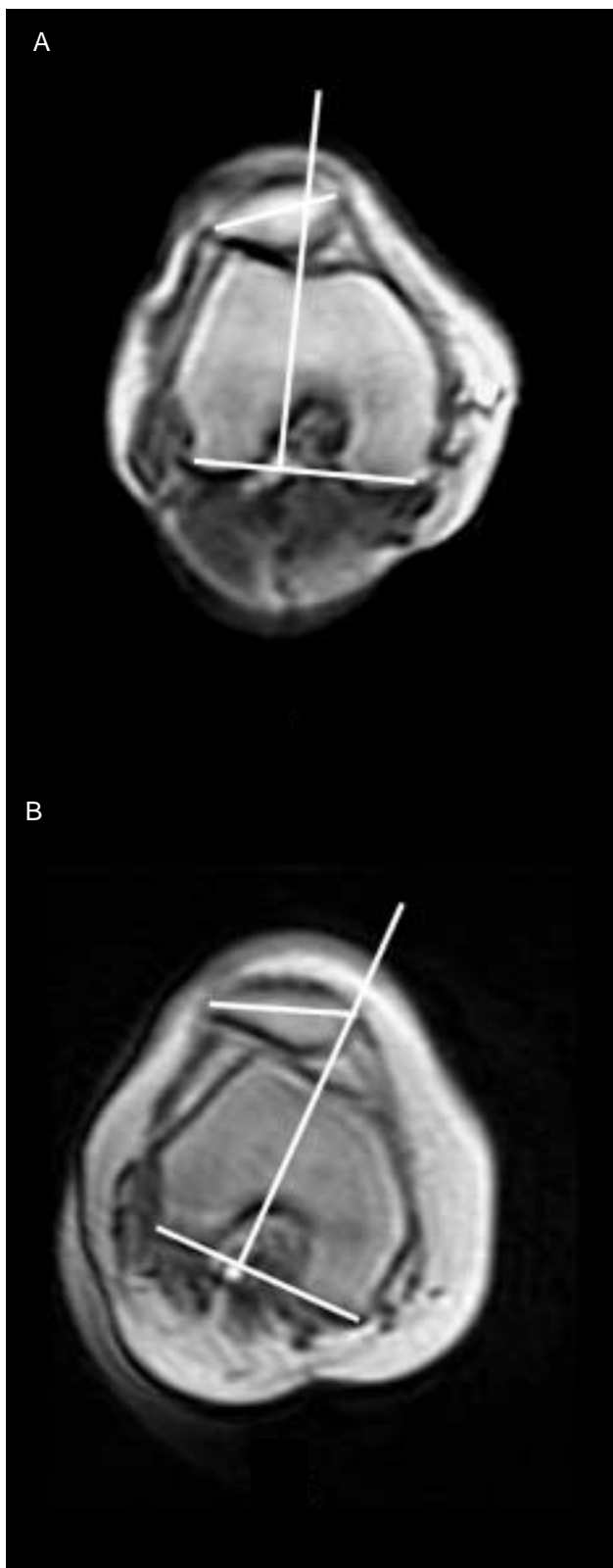


FIGURE 10. Influence of femoral rotation on lateral patellar tilt at  $0^\circ$  of knee flexion. During the non-weight-bearing condition (A), lateral patellar tilt was the result of the patella rotating ( $\alpha$ ) on a relatively horizontal femur ( $\theta$ ). During the weight-bearing condition (B), lateral patellar tilt was the result of an internally rotating femur ( $\theta$ ) under a relatively horizontal patella ( $\alpha$ ).

The premise that femoral rotation may play a role in contributing to patellar malalignment during weight-bearing activities is consistent with observations of Tennant et al.<sup>20</sup> However, because these authors only evaluated nonpainful knees and did not quantify the magnitude of femoral rotation, comparisons to the current investigation are not possible. Furthermore, whether or not the amount of femoral rotation observed in the current investigation was excessive cannot be determined. Control group data would be needed to fully clarify this issue and certainly should be a focus of future investigations.

Care must be taken in generalizing the results of this study to the entire population of individuals with PFP, as only 6 subjects were evaluated. It also should be noted that the individuals recruited for this study demonstrated lateral subluxation of the patella and may not be representative of all persons with PFP. For



**FIGURE 11.** Influence of femoral rotation on lateral patellar displacement at 0° of knee flexion. During the non-weight-bearing condition (A), lateral patellar displacement was the result of the patella moving on a fixed femur. During the weight-bearing condition (B), lateral patellar displacement was influenced by the femur rotating under the patella.

example, it has been reported that not all individuals with PFP demonstrate abnormal patellofemoral kinematics.<sup>14,17</sup> This also was reflected in the current study, as 12 persons with PFP had to be screened to enroll the 6 that were studied. Given the preliminary nature of the results presented, future research should be directed towards comparing patellofemoral kinematics between weight-bearing and non-weight-bearing exercises in a larger sample of persons with lateral patellar subluxation, and should also include a control group for proper comparisons.

## CONCLUSION

The results of this study demonstrated that lateral patellar displacement was more pronounced during non-weight-bearing knee extension as compared to weight-bearing knee extension in persons with lateral patellar subluxation. In addition, the results of this investigation suggest that the patellofemoral joint kinematics during non-weight-bearing could be characterized as the patella rotating on the femur, while the patellofemoral joint kinematics during the weight-bearing condition could be characterized as the femur rotating underneath the patella.

## REFERENCES

1. Delgado H. A study of the position of the patella using computerized tomography. *J Bone Joint Surg Am.* 1979;61B:443-444.
2. Doucette SA, Child DD. The effect of open and closed chain exercise and knee joint position on patellar tracking in lateral patellar compression syndrome. *J Orthop Sports Phys Ther.* 1996;23:104-110.
3. Fulkerson JP, Shea KP. Mechanical basis for patellofemoral pain and cartilage breakdown. In: Ewing JW, ed. *Articular Cartilage and Knee Joint Function: Basic Science and Arthroscopy.* New York, NY: Raven Press; 1990:93-101.
4. Grana W, Kriegshauser L. Scientific basis of extensor mechanism disorder. *Clin Sports Med.* 1985;4:247-257.
5. Heywood WB. Recurrent dislocation of the patella. *J Bone Joint Surg Am.* 1961;42B:508-517.
6. Levine J. Chondromalacia patella. *Phys Sportsmed.* 1979;7:41-49.
7. Merchant AC, Mercer RL, Jacobsen RH, Cool CR. Roentgenographic analysis of patellofemoral congruence. *J Bone Joint Surg Am.* 1974;56:1391-1396.
8. Moller BN, Moller-Larsen F, Frich LH. Chondromalacia induced by patellar subluxation in the rabbit. *Acta Orthop Scand.* 1989;60:188-191.
9. Morrish GM, Woledge RC. A comparison of the activation of muscles moving the patella in normal subjects and in patients with chronic patellofemoral problems. *Scand J Rehabil Med.* 1997;29:43-48.
10. Powers CM. Patellar kinematics, part II: the influence of the depth of the trochlear groove in subjects with and without patellofemoral pain. *Phys Ther.* 2000;80:965-978.
11. Powers CM, Perry J, Hsu A, Hislop HJ. Are patellofemoral pain and quadriceps femoris muscle torque



- associated with locomotor function? *Phys Ther.* 1997;77:1063-1075; discussion 1075-1068.
12. Powers CM, Shellock FG, Beering TV, Garrido DE, Goldbach RM, Molnar T. Effect of bracing on patellar kinematics in patients with patellofemoral joint pain. *Med Sci Sports Exerc.* 1999;31:1714-1720.
  13. Powers CM, Shellock FG, Pfaff M. Quantification of patellar tracking using kinematic MRI. *J Magn Reson Imaging.* 1998;8:724-732.
  14. Schutzer SF, Ramsby GR, Fulkerson JP. The evaluation of patellofemoral pain using computerized tomography. A preliminary study. *Clin Orthop.* 1986;286-293.
  15. Shellock FG, Mink JH, Deutsch A, Foo TK. Kinematic MRI of the patellofemoral joint. In: Shellock FG, Powers CM, eds. *Kinematic MRI of the Joints: Functional Anatomy, Kinesiology, and Clinical Applications.* Boca Raton, FL: CRC Press LLC; 1992.
  16. Shellock FG, Mink JH, Deutsch A, Fox JM, Ferkel RD. Evaluation of patients with persistent symptoms after lateral retinacular release by kinematic magnetic resonance imaging of the patellofemoral joint. *Arthroscopy.* 1990;6:226-234.
  17. Shellock FG, Mink JH, Deutsch AL, Foo TK. Kinematic MR imaging of the patellofemoral joint: comparison of passive positioning and active movement techniques. *Radiology.* 1992;184:574-577.
  18. Shellock FG, Mink JH, Deutsch AL, Foo TK, Sul- lenberger P. Patellofemoral joint: identification of abnor- malities with active-movement, "unloaded" versus "loaded" kinematic MR imaging techniques. *Radiology.* 1993;188:575-578.
  19. Shellock FG, Mink JH, Deutsch AL, Fox JM. Patellar tracking abnormalities: clinical experience with kine- matic MR imaging in 130 patients. *Radiology.* 1989;172:799-804.
  20. Tennant S, Williams A, Vedi V, Kinmont C, Gedroyc W, Hunt DM. Patello-femoral tracking in the weight- bearing knee: a study of asymptomatic volunteers utilising dynamic magnetic resonance imaging: a pre- liminary report. *Knee Surg Sports Traumatol Arthrosc.* 2001;9:155-162.
  21. Ward SR, Shellock FG, Terk MR, Salsich GB, Powers CM. Assessment of patellofemoral relationships using kinematic MRI: comparison between qualitative and quantitative methods. *J Magn Reson Imaging.* 2002;16:69-74.
  22. Ward SR, Souza RB, Powers CM. Error associated with MRI based measurements of patellofemoral alignment: the influence of the femoral motion. *XIXth Internation Society of Biomechanics Congress.* Dunedin, New Zealand: 2003.
  23. Witonski D, Goraj B. Patellar motion analyzed by kinematic and dynamic axial magnetic resonance imag- ing in patients with anterior knee pain syndrome. *Arch Orthop Trauma Surg.* 1999;119:46-49.